

Case report

Pulmonary alveolar microlithiasis and interstitial pneumonitis: a case report of the west of Iran

Mazaher Ramezani¹, Zahra Aminparast², Masoud Sadeghi^{3,2,*}

¹Molecular Pathology Research Center, Imam Reza Hospital, Kermanshah University of Medical Sciences, Kermanshah, Iran

²Students Research Committee, Kermanshah University of Medical Sciences, Kermanshah, Iran

³Medical Biology Research Center, Kermanshah University of Medical Sciences, Kermanshah, Iran

Received 7th of March, 2019 Accepted 2nd of May, 2019

© Author(s) 2019. This article is published with open access by China Medical University

Keywords:

Pulmonary alveolar microlithiasis;
Case report;
Interstitial pneumonitis

ABSTRACT

Pulmonary alveolar microlithiasis (PAM) is a rare disease with autosomal recessive inheritance. Herein, a 20-year-old lady referred to the hospital with a dry cough for two years. The chest X-ray findings were bilateral reticulonodular opacities in both lungs and honeycomb appearance suspicious for miliary tuberculosis and idiopathic pulmonary fibrosis. A wedge biopsy of lung showed that there were several intraalveolar laminated concretions in the pathology report compatible with pulmonary alveolar microlithiasis and interstitial infiltration of lymphocytes and neutrophils compatible with interstitial pneumonitis. PAM is a rare progressive disease with the production of microliths in pulmonary alveoli. The pathologist, radiologist, and clinician should be familiar with this entity for diagnosis and appropriate management. The family of the patient especially siblings must be evaluated for earlier diagnosis.

1. Introduction

Pulmonary alveolar microlithiasis (PAM) is a rare disease with autosomal recessive inheritance which affects mainly the patients between 20s and 40s [1-4]. The pathogenesis of the disease is known to be a mutation in the gene which encodes sodium-dependent phosphate cotransporter. Accumulation of phosphorous from a degraded surfactant in the pulmonary alveoli makes a nidus for microliths or stone lungs [1, 2, 5-9]. The stones are mainly made of calcium phosphate with a lamellated or psammoma-body appearance in histologic sections [1, 2]. In the early phase, most of the patients are asymptomatic. As the disease progresses, the presentation will be a dry cough, dyspnea on exertion, cyanosis, chest pain, hemoptysis or pneumothorax [1, 2, 5, 10]. Finally, the disease will progress to cor pulmonale and respiratory failure [2]. Approximately, one thousand cases are reported in the world right now and most of the articles in the literature are case reports [2]. Diagnosis is possible by imaging, but a definite diagnosis requires a pulmonary biopsy [5, 11]. PAM is in differential diagnosis with other disorders especially pulmonary tuberculosis and may be prescribed unnecessary antitubercular therapy mainly in endemic

areas [2, 12]. Herein, we report a rare case of PAM associated with interstitial pneumonitis with the classic presentation which is diagnosed in histopathology examination of lung biopsy in the west of Iran.

2. Case report

A 20-year-old lady referred to the hospital with a chief complaint of dry cough since 2 years ago on 31st December 2018 to the department of thoracic surgery for lung biopsy. Severe cough attack lasted 5-10 minutes each time. Attacks were more severe for 3-4 days. Past medical history, drug history, and family history were unremarkable. There was no dyspnea or respiratory distress, fever and chills, nausea or vomiting. The physical examination was unremarkable including stable vital signs. Temperature: 37°C, Pulse rate: 78/min, Respiratory rate: 19/min and Blood pressure: 110/60 mmHg. Chest wall was symmetric with soft abdomen. No heart murmur or abdominal tenderness was noted. The general condition was good. The chest X-ray findings were bilateral reticulonodular opacities in both lungs (Pneumonia) and

*Corresponding author. Medical Biology Research Center, Kermanshah University of Medical Sciences, Daneshgah St., Shahid Shiroodi Blv., 6714415185 Kermanshah, Iran.
E-mail address: sadeghi_mbrc@yahoo.com (M. Sadeghi).

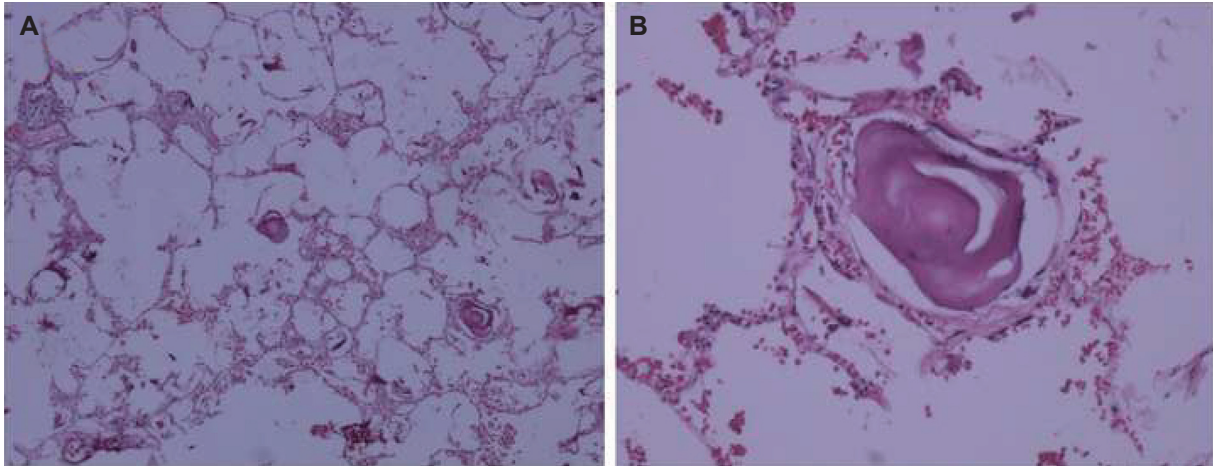


Fig. 1 - Pulmonary Alveolar Microlithiasis showing microliths in alveolar spaces. (Hematoxylin-Eosin staining with magnifications of A $\times 40$ and B $\times 200$)

honeycomb appearance (Bronchiectasis) suspicious for miliary tuberculosis and idiopathic pulmonary fibrosis. Opacity and mucosal thickness in maxillary sinuses suggested sinusitis. The ultrasound revealed diffuse opacities in both lungs. Meanwhile, bilateral axillary lymphadenopathy measuring 11-13 mm with reactive appearance was present. Spiral Computed Tomography (CT) scanning without contrast of lung and mediastinum revealed evidence of diffuse opacities of reticulonodular pattern in both parenchymas suggestive of miliary tuberculosis and less probable military metastasis. A few foci of linear fibrosis and air trapping in both lungs' parenchyma were also noted. Clinically, sarcoidosis was also in differential diagnosis. Bronchoalveolar lavage demonstrated no evidence of malignancy and evidence of chronic inflammation and calcification. The lab data including urea (17 mg/dl), creatinine (0.7 mg/dl), Na (137 mEq/l), K (4 mEq/l), and blood sugar (130 mg/dl) were within normal limits. Prothrombin Time (PT): 13.7 second, International Normalized Ratio (INR): 1, Partial Thromboplastin Time (PTT): 24 second and liver function tests were also within normal limits. White blood cell counts were 18.3 and 16.2×10^3 /microliter at two consequent days. Neutrophils were about 85%. Hemoglobin and platelets were unremarkable. The left lateral thoracotomy with a primary diagnosis of idiopathic pulmonary fibrosis was done and wedge biopsy from the left lower lobe was taken. The specimen consisted of a tan-brownish piece of tissue measuring $2.5 \times 2 \times 0.5$ cm. The pathology report showed several intra alveolar laminated concretions compatible with PAM. The lung tissue showed interstitial infiltration of lymphocytes and neutrophils compatible with interstitial pneumonitis (Figure 1).

3. Discussion

PAM is rare, but most cases are from Asia and Europe. In Asia, the total number of cases in the review of Castellana *et al.* [2] from Iran was 26 ranking 5th after Turkey, China, Japan and India. The disease is slightly more prevalent in men [2]. Although the disease is rare in Africa, Zaghba *et al.* [13] reported a 42-year-old African lady with PAM by chest X-ray, chest CT scan, and

transbronchial biopsy. These tools were also used by researchers of Turkey for confirmation of their case of PAM [14].

Devine *et al.* [15] reported a 56-year-old Turkish man of PAM presented with mild dyspnea and a lifelong history of chronic lung disease. Despite pneumothorax, his patient was asymptomatic at rest. Familial cases of PAM are reported in the literature with a positive family history in 37.2% of cases [1, 2]. One study [16] from China reported 3 cases of PAM, two of them had consanguinity. PAM has been seen in all age groups, but most cases are between 20 and 40 [2] however, Stamatoopoulos and the colleagues reported a 63-year-old man with a positive family history as an unusually late-onset disease [17]. Gupta *et al.* [18] diagnosed their case of PAM by adding a new pattern to radiologic pictures of PAM, as "dense confluent calcifications caused consolidation of the lungs" on high resolution computed tomographic scan of the lung. Two studies [19, 20] reported PAM cases with Clinico-Radiological dissociation that one study [19] showed a silent clinic with extensive changes on imaging and biopsy, whereas another study [20] confirmed the diagnosis by bronchoscopic alveolar lavage and demonstration of calcospherites.

Some researchers believe that radiology is enough, for diagnosis of PAM, when findings are typical in an asymptomatic patient. Differential diagnosis of an asymptomatic patient with chest X-ray showing dense micronodular and ground glass opacities, is mainly miliary tuberculosis, pulmonary alveolar proteinosis, sarcoidosis, resolved varicella pneumonia, metastatic calcification, pneumoconiosis and amyloidosis [1, 2]. Patchy inflammation and pulmonary fibrosis are frequently seen in PAM [1]. Present case had interstitial inflammation mainly of lymphocytes. Others reported lymphocytic interstitial pneumonitis in PAM, but it may be an association by chance [1]. Long-term prognosis is poor and the disease may culminate in respiratory failure [1]. Smoking, inflammation, and cold temperature may deteriorate the patient's condition [2]. Etidronate as a bisphosphonate, steroid hormones and repeated lavage are controversial medical treatments. Supplemental oxygen therapy and vaccination against pneumococcus and influenza are necessary for patients. Lung transplanted patients had no recurrence of the disease [1]. Gene therapy may be a promising treatment in the future [2].

4. Conclusions

PAM is a rare progressive disease with the production of micro-liths in pulmonary alveoli. This entity has the characteristic radiologic picture in a silent clinical background and can be proven cytologically or histologically by bronchoalveolar lavage or lung biopsy, respectively. The pathologist, radiologist, and clinician should be familiar with this entity for diagnosis and appropriate management. The patient's family especially siblings must be evaluated for earlier diagnosis.

Acknowledgements

The invaluable work of Ms. Sholeh Akradi for providing data is greatly appreciated. The authors would like to thank the Clinical Research Development Center of Imam Reza Hospital for Consulting Services.

Conflicts of interest statement

The authors wish to disclose no conflicts of interest.

Open Access This article is distributed under terms of the Creative Commons Attribution License which permits any use, distribution, and reproduction in any medium, provided original author(s) and source are credited.

REFERENCES

- [1] Saito A, McCormack FX. Pulmonary Alveolar Microlithiasis. *Clin Chest Med.* 2016; 37(3): 441-8.
- [2] Castellana G, Castellana G, Gentile M, Castellana R, Resta O. Pulmonary alveolar microlithiasis: review of the 1022 cases reported worldwide. *Eur Respir Rev.* 2015; 24(138): 607-20.
- [3] Asciak R, Pullicino R, Mizzi A, Montefort S. A rare case of pulmonary alveolar microlithiasis. *BMJ Case Rep.* 2015; 2015: bcr2015212804.
- [4] Mehrian P, Khalilzadeh S, Hassanzad M, Hasani Z, Nejad ST, Velayati AA. Pediatric pulmonary alveolar microlithiasis: a case report. *Tanaffos.* 2013; 12(4): 58-60.
- [5] Mehta K, Dell S, Birken C, Al-Saleh S. Pulmonary Alveolar Microlithiasis. *Can Respir J.* 2016; 2016: 4938632.
- [6] Huqun, Izumi S, Miyazawa H, Ishii K, Uchiyama B, Ishida T, *et al.* Mutations in the SLC34A2 gene are associated with pulmonary alveolar microlithiasis. *Am J Respir Crit Care Med.* 2007; 175(3): 263-8.
- [7] Vismara MF, Colao E, Fabiani F, Bombardiere F, Tamburrini O, Alessio C, *et al.* The sodium-phosphate co-transporter SLC34A2, and pulmonary alveolar microlithiasis: Presentation of an inbred family and a novel truncating mutation in exon 3. *Respir Med Case Rep.* 2015; 16: 77-80.
- [8] Dandan S, Yuqin C, Wei L, Ziheng P, Dapeng Z, Jianzhu Y, *et al.* Novel deletion of SLC34A2 in Chinese patients of PAM shares mutation hot spot with fusion gene SLC34A2- ROS1 in lung cancer. *J Genet.* 2018; 97(4): 939-44.
- [9] Ma T, Qu D, Yan B, Zhang Q, Ren J, Hu Y. Effect of SLC34A2 gene mutation on extracellular phosphorus transport in PAM alveolar epithelial cells. *Exp Ther Med.* 2017; 15(1): 310-4.
- [10] Sigari N, Nikkhoo B. First presentation of a case of pulmonary alveolar microlithiasis with spontaneous pneumothorax. *Oman Med J.* 2014; 29(6): 450-3.
- [11] Santos MK. Diagnosis of pulmonary alveolar microlithiasis. *Radiol Bras.* 2015; 48(5): IX-X.
- [12] Khurana A, Malik R, Sharma J, Khurana U, Joshi D, Goyal A. Pulmonary Alveolar Microlithiasis: A commonly misdiagnosed rare entity. *Sultan Qaboos Univ Med J.* 2018; 18(2): e236-e238.
- [13] Zaghba N, Hachimi KE, Benjelloun H, Yassine N. La microlithiase alvéolaire: à propos d'une nouvelle observation [Alveolar microlithiasis: about a new case]. *Pan Afr Med J.* 2017; 28: 241.
- [14] Arpağ H, Sayan M, Atilla N, Bozkuş F, Bahar AY, Kahraman H, *et al.* A Case of Pulmonary Alveolar Microlithiasis Diagnosed by Transbronchial Biopsy. *Turk Thorac J.* 2017; 18(4): 134-6.
- [15] Devine OP, Harborne AC. Pneumothorax secondary to pulmonary alveolar microlithiasis. *Clin Case Rep.* 2018; 6(4): 764-5.
- [16] Zhang XD, Gao JM, Luo JM, Zhao Y. Pulmonary alveolar microlithiasis: A case report and review of the literature. *Exp Ther Med.* 2017; 15(1): 831-7.
- [17] Stamatopoulos A, Patrini D, Mitsos S, Khiraya R, Borg E, Hayward M1, *et al.* An unusual late onset of pulmonary alveolar microlithiasis: A case report and literature review. *Respir Med Case Rep.* 2017; 22: 24-7.
- [18] Gupta PK, Mittal R, Chhabra SK. Calcified pulmonary consolidations in pulmonary alveolar microlithiasis: Uncommon computed tomographic appearance of a rare disease. *Lung India.* 2017; 34(3): 297-9.
- [19] Chu A, Shaharyar S, Chokshi B, Bhardwaj N. Pulmonary Alveolar Microlithiasis "Stone Lungs": A Case of Clinico-Radiological Dissociation. *Cureus.* 2016; 8(8): e749.
- [20] Mahmood K, Ubaid M, Mahmood A. Pulmonary microlithiasis - A case report. *Respir Med Case Rep.* 2016; 19: 112-4.